Diagnostic et traitement du cancer de la prostate

Raphaële Renard-Penna (Paris)
Höpital Pitié Salpétrière APHP

1er au 2 décembre 2021 au Palais des Congrès de Paris

DETECTION DU CANCER DE PROSTATE : STRATEGIE SANS IMAGERIE

1ere étape: évaluation du risque

2ème étape: BIOPSIE

Risque de cancer de prostate

- **ATCD familiaux**
- **PSA**
- **PSAD**
- **TR**
- **Biopsies antérieures**

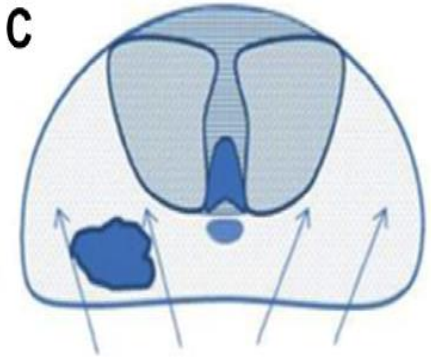

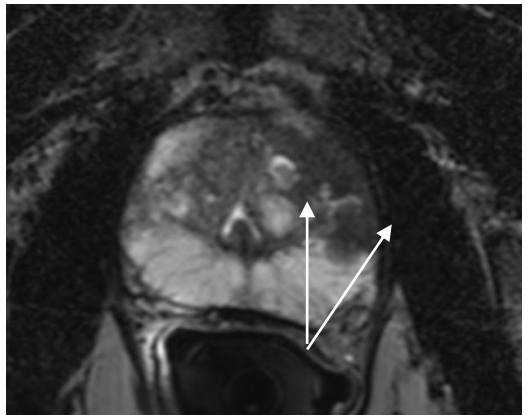

SYSTEMATIC BIOPSIES (SB)

1. **Cancers significatifs manqués**
2. **Détection trop importante de cancers insignifiants**

Diagnostic précoce du cancer de la prostate

PSA :

- Marqueur du tissu prostatique
- Marqueur de l'HBP > marqueur du cancer de prostate

TR:

- Spécifique et peu sensible

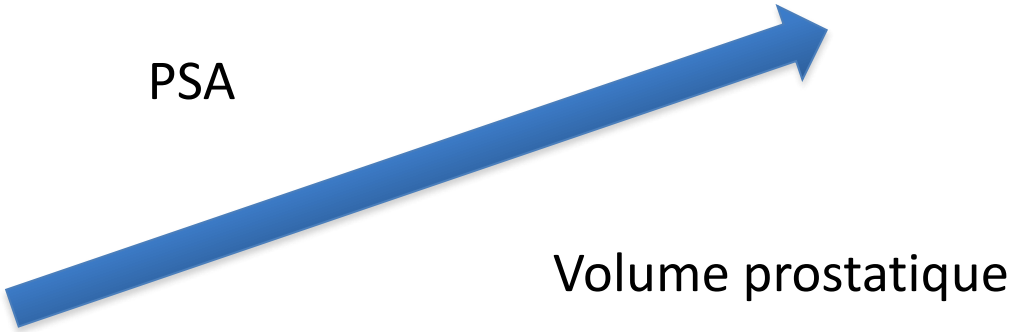

William J. Catalona JAMA 1998;279(19):1542-1547.

STRATEGIE BASEE SUR L'IMAGE

1ere étape: évaluation du risque

Risque de cancer de prostate

- **ATCD familiaux**
- **PSA**
- **PSAD**
- **TR**
- **Biopsies antérieures**

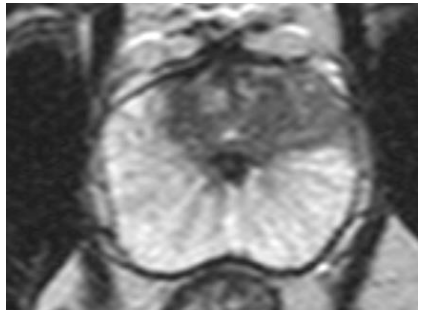

2ème étape: BIOPSIE



Biopsies Ciblées

OU

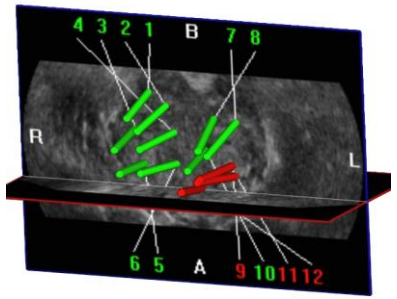

TB + SB

BP ST

OU

PAS DE BIOPSIES

Diagnostic précoce du cancer de la prostate: IRM prostatique

Détection - Caractérisation (volume-agressivité) – Localisation- Extension

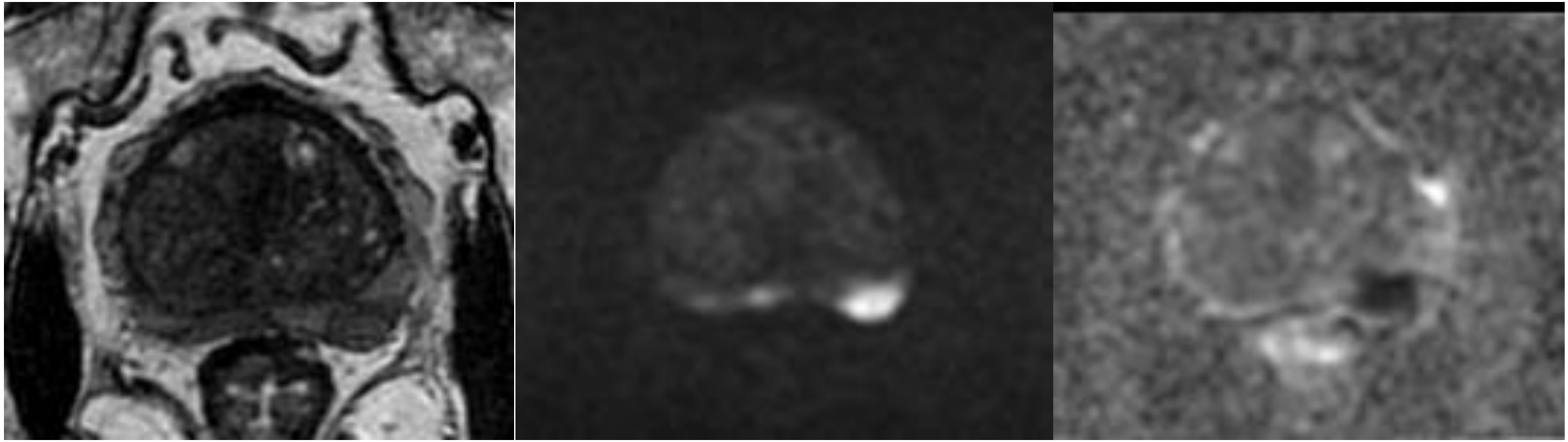

T2W DW DCE

IRM prostatique: performance

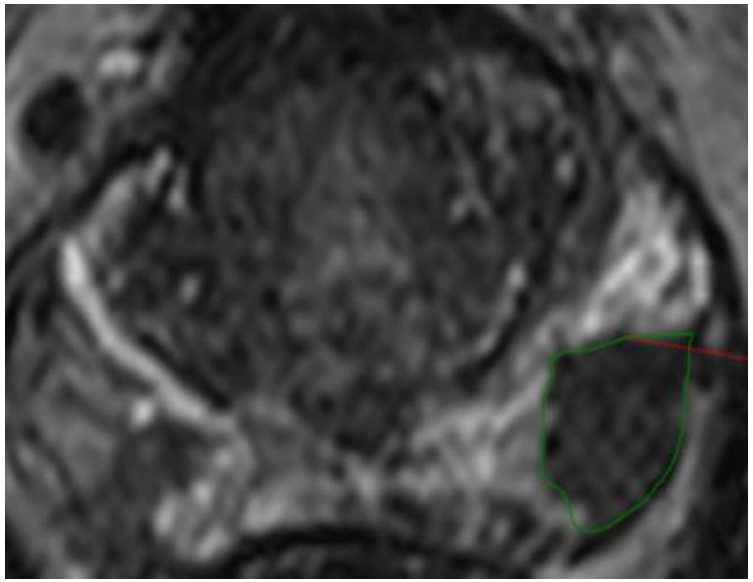

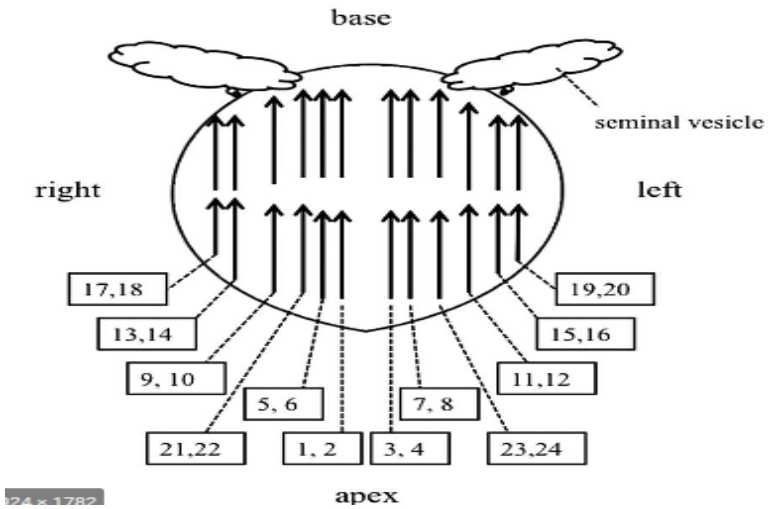

IRM prostatique performante pour la détection des lésions dites « significatives »

VPN 89 %

Ahmed et al, Promis, Lancet 2017

IRM AVANT BIOPSIES CIBLEES: LE NOUVEAU PARADIGME

IRM + biopsies ciblées

- 1. Augmente la détection **des cancers significatifs** ISUP grade 2 PCa
- 2. Réduit la détection des **cancers insignifiants**
- 3. Evite des **biopsies inutiles**
  - PROMIS , PRECISION trials, MRI first

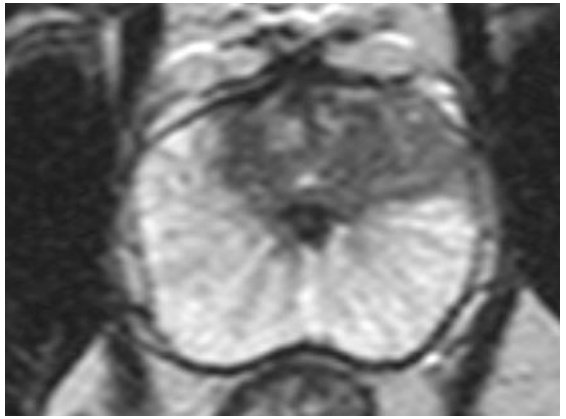

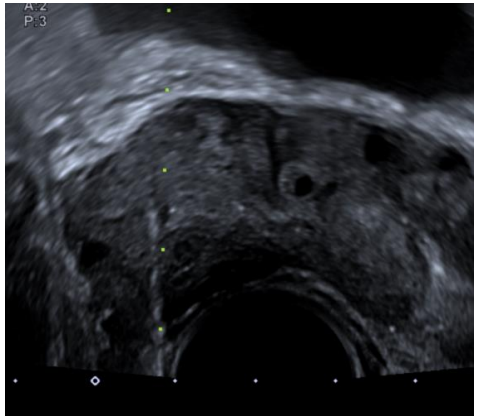

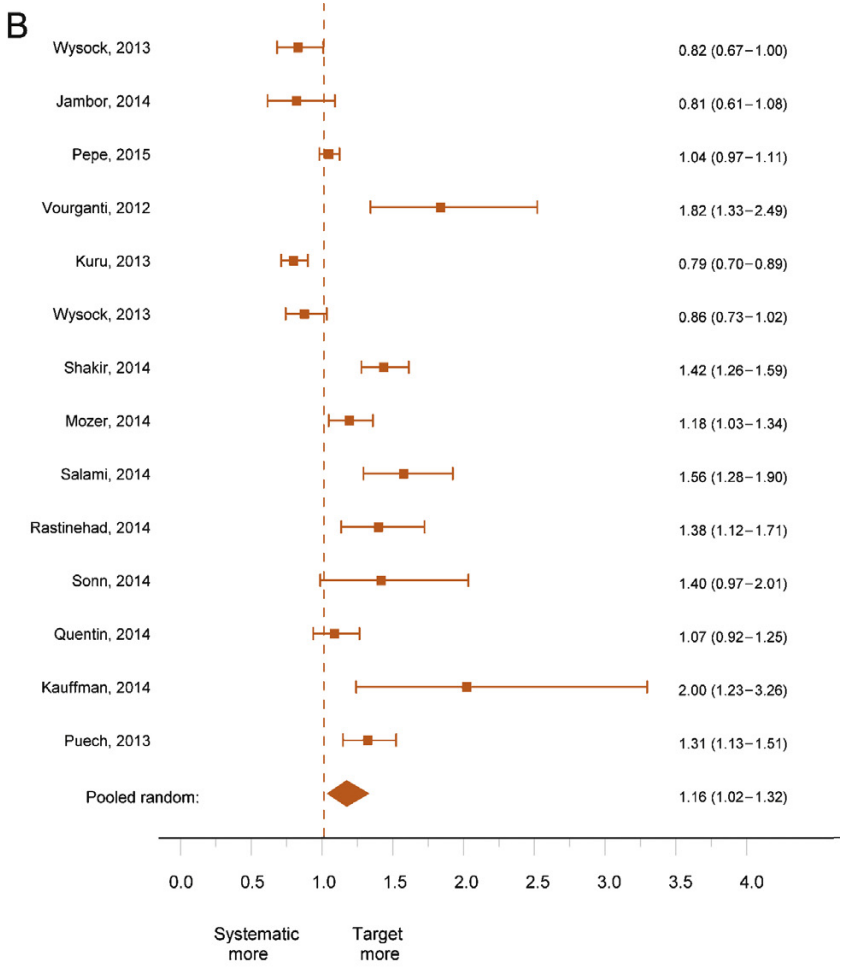

Wegelin et al, Eur Urol 2017

ASSOCIATION FRANÇAISE D'UROLOGIE

IRM prostatique: standardisation de l'interprétation- PI RADS score

1	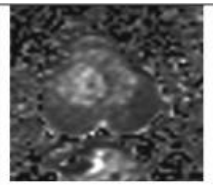		No abnormality (i.e. normal) on ADC and high b- value DWI.
2	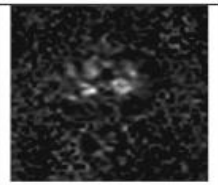	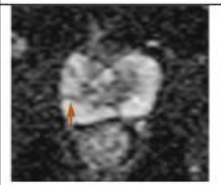	Indistinct hypointense on ADC (*arrow*).
3	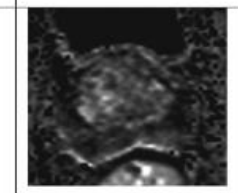	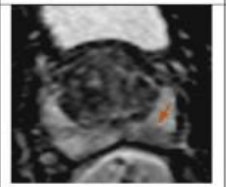	Focal mildly/moderately hypointense on ADC (*arrow*) and isointense/mildly hyperintense on high b-value DWI.
4	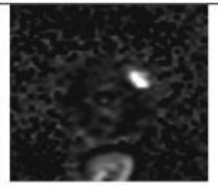	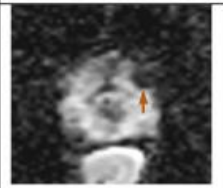	Focal markedly hypointense on ADC (*arrow*) and markedly hyperintense on high b-value DWI; <1.5cm on axial images.
5	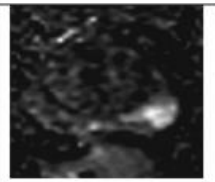	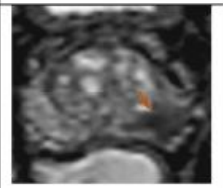	Same as 4 but ≥1.5cm in greatest dimension (*arrow*) or definite extraprostatic extension / invasive behavior.
	High b-value DWI	ADC map	

1: non suspect

3

5: suspect

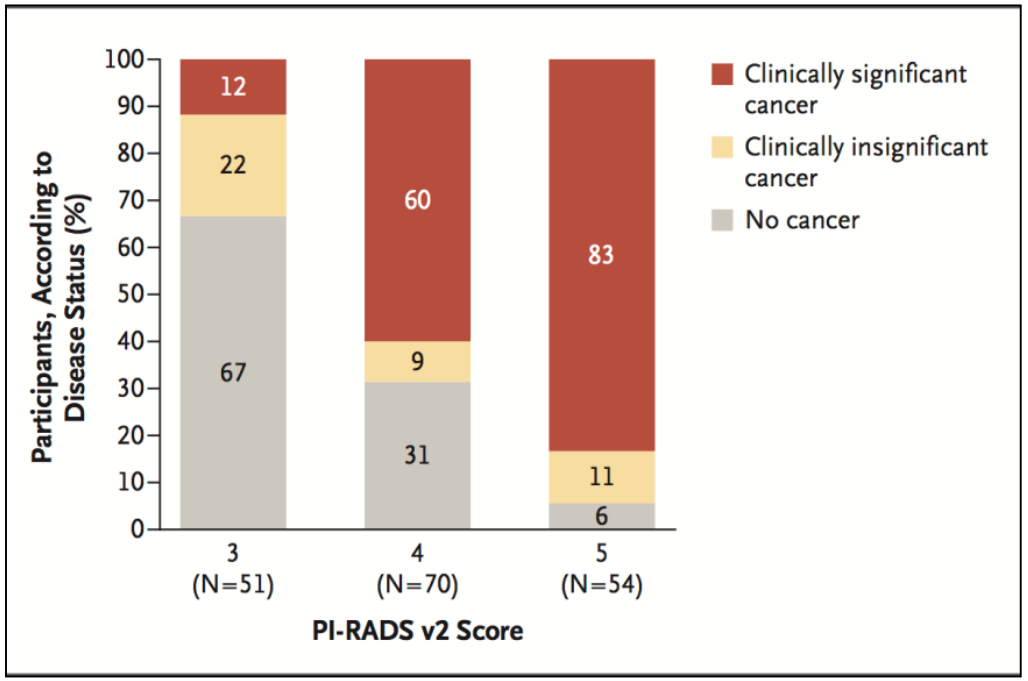

Weinreb et al. Eur urol 2016
Kasivisvanathan K et al NEJM 2018

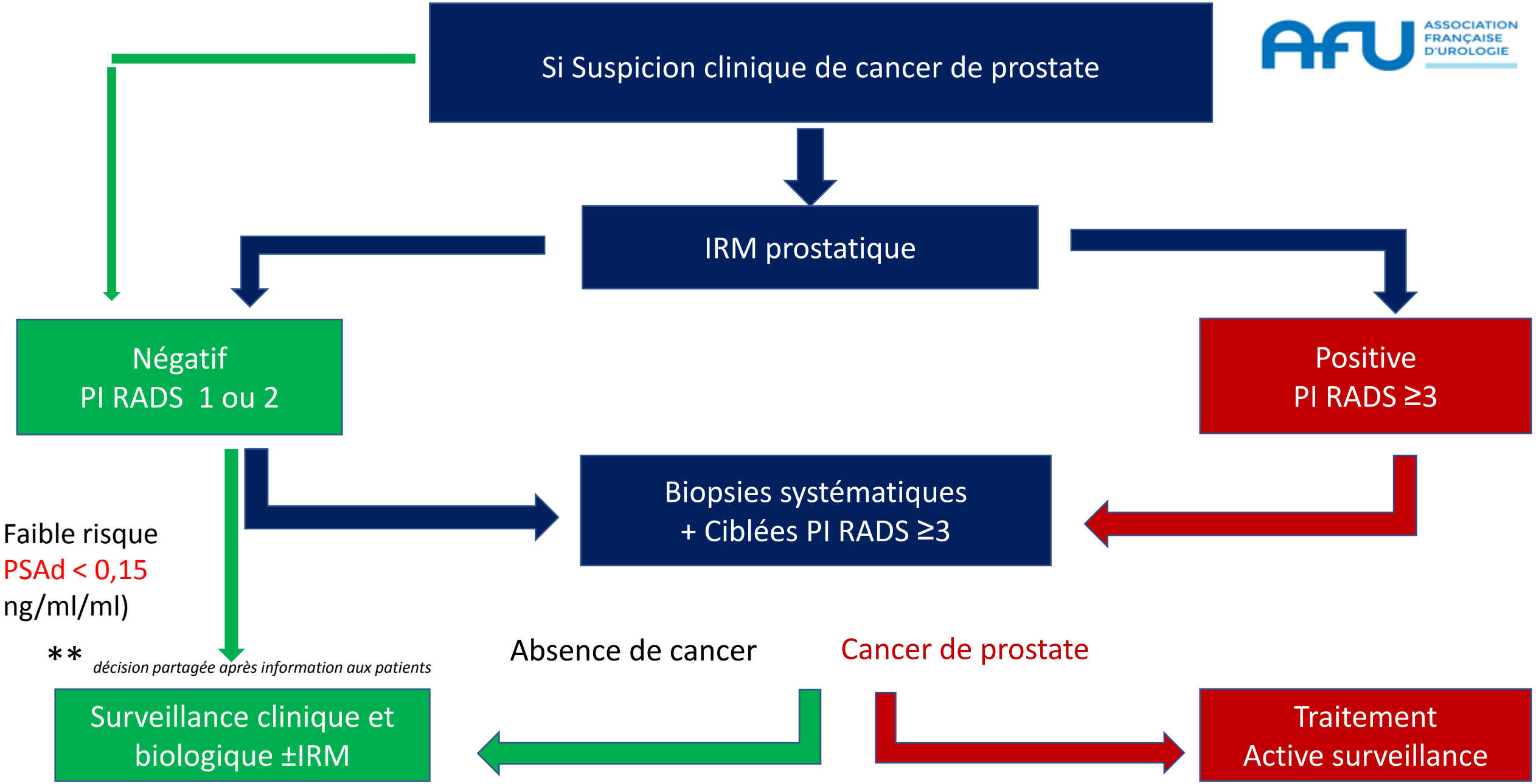

AFU : Rozet F, et al. Recommandations françaises du Comité de Cancérologie de l'AFU – Actualisation 2020 : cancer de la prostate. Prog Urol 2020

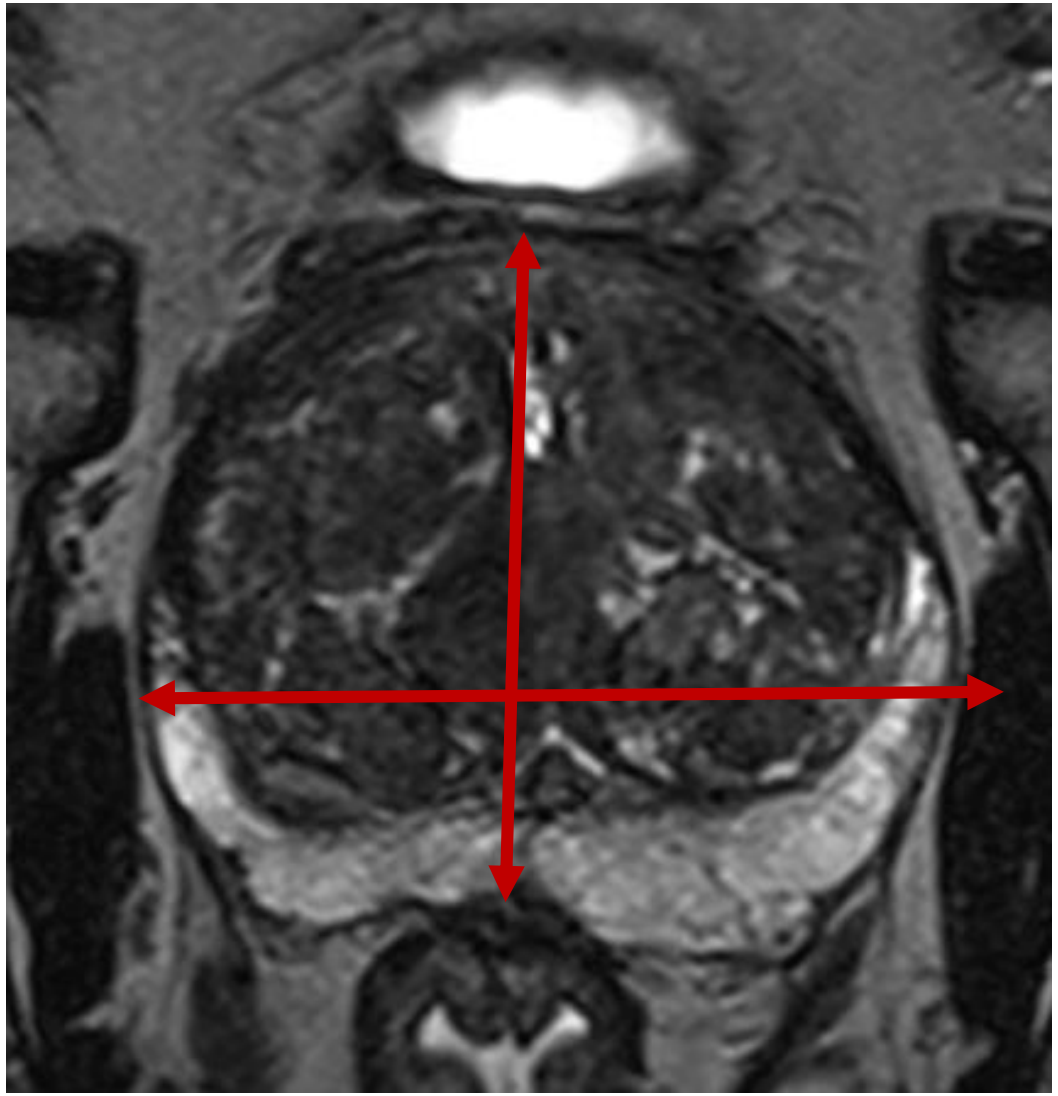

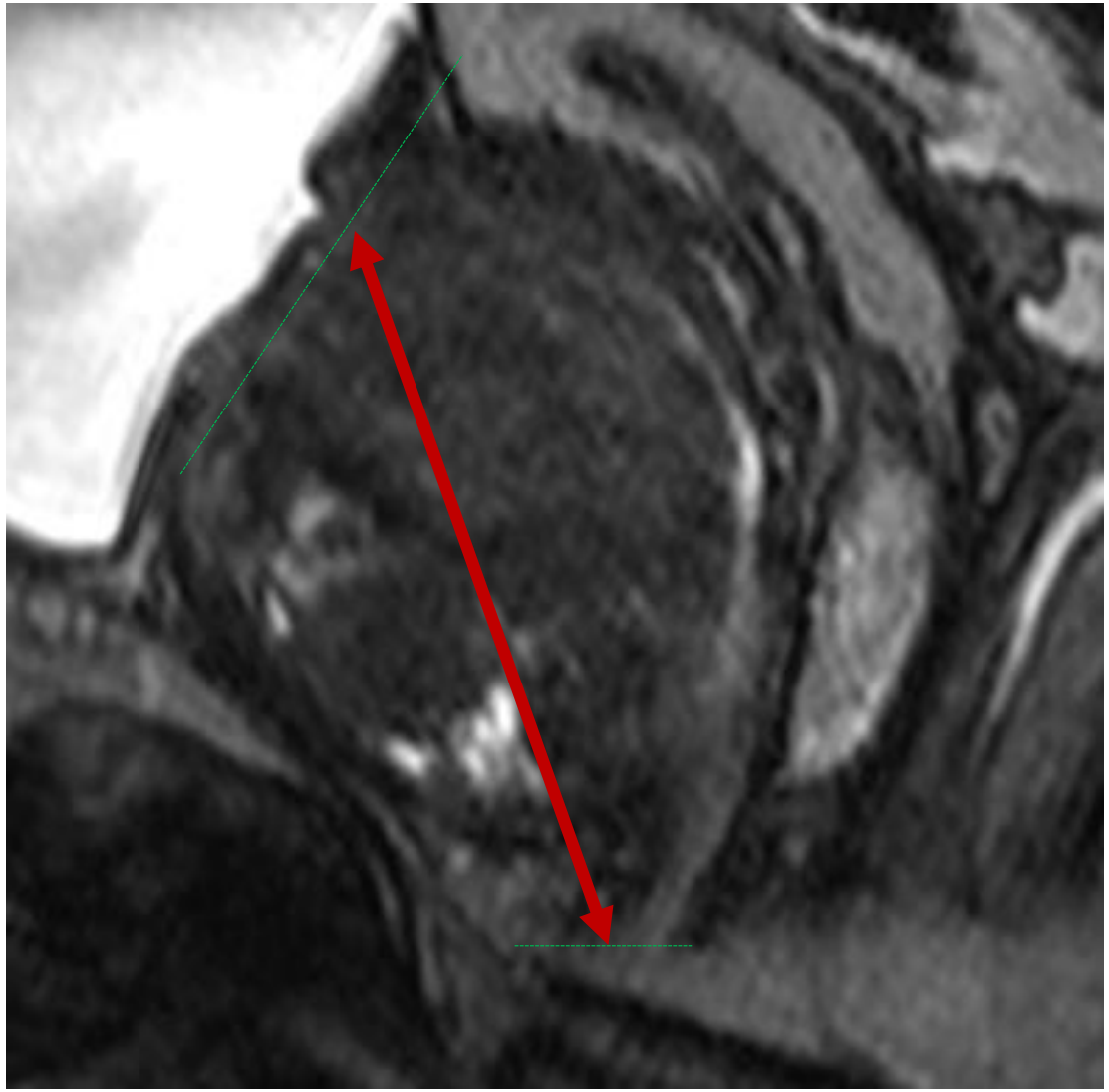

PSAd (ng/mL:cm_3) : ratio du taux de PSA (ng/mL) / volume prostatique (mL)